

**PATIENT**

Carter Lincoln

**PRESENTING CLINICAL SIGNS**

History: Arrhythmia noted on exam. VPCs noted 11/2022. BP: 116, 117, 120mmHg.

**SPECIES**

Canine

**ELECTROCARDIOGRAPHIC FINDINGS** \*Note: Single lead ECGs are evaluated as a rhythm strip. Morphology/MEA cannot be definitively commented on.

A single lead ECG is available; 25mm/s, 20mm/mV. The average heart rate is 120bpm (range 100-150bpm). The rhythm is sinus in origin, with a p for every QRS complex and vice versa. P and QRS morphologies are positive. Frequent isolated VPCs are seen throughout; singles only and monomorphic. No supraventricular premature beats, pauses or other dysrhythmias observed.

**BREED**

Boxer

ECG diagnosis: Normal sinus rhythm with isolated monomorphic VPCs.

**SEX**

Female Spayed

**ECHOCARDIOGRAM FINDINGS**

2D, m-mode, color flow and Doppler imaging is available.

**AGE**

11 years

**Left ventricle:** The LV diameter is normal with adequate myocardial function. LV wall thicknesses are normal.

**Left atrium:** The left atrium is normal.

**Mitral valve:** The mitral valve is normal with trivial MR.

**Aortic valve/Aorta:** The aortic valve is normal with normal mobility. Normal aortic outflow velocity; laminar flow. No aortic insufficiency.

**WEIGHT**

49lbs

**Right ventricle:** Normal right ventricular diameter and morphology indicating no overt evidence of pulmonary arterial hypertension.

**Right atrium:** Normal RA dimension.

**Tricuspid valve:** The tricuspid valve appears normal with no tricuspid regurgitation.

**Pulmonic valve/Pulmonary artery:** The pulmonic valve is normal in morphology and mobility. No pulmonic insufficiency. Normal RVOT velocity; laminar flow.

**Pericardium/other:** No pericardial or pleural effusion noted. No obvious cardiac masses.

**INTERPRETED BY**

Maggie Machen  
Lamy, DVM  
DACVIM (Cardiology)

**2-Dimensional Measurements**

Ao diam (cm)	2.1
LA diam (cm)	2.4
LA:Ao (Swe)	1.2
IVS thickness (cm)	1.1
LVID diastole (cm)	2.8
PW thickness (cm)	1.1
LVID systole (cm)	1.8
FS (%)	36

**Doppler Measurements**

PV Vmax (m/s)	0.63
AoV Vmax (m/s)	1.4
MR Vmax (m/s)	NA
TR Vmax (m/s)	NA
TR PG (mmHg)	NA

**IMAGING PERFORMED BY**

Pamela Harrigan,  
RDCS

**HOSPITAL NAME**

VCA Palmer

**REFERRING VET**

Dr. Boudreau

**INTERPRETATION OF THE FINDINGS**

Overtly normal cardiac structure and function. No structural issues or cardiac tumors are identified. That being said, small extra-cardiac masses are easily missed, and this is not entirely ruled out on 2D ultrasound.

**INVOICE**

29111

Isolated VPCs are confirmed on the ECG. VPCs are ectopic beats generated from abnormal conductive or fibrotic tissue in the ventricles of the heart muscle, and even frequent single VPCs will often cause no clinical signs in dogs. When sustained however, ventricular tachycardia can lead to symptoms such as lethargy and collapse.

**DATE**

2/20/23



**PATIENT**

Carter Lincoln

**SPECIES**

Canine

**BREED**

Boxer

**SEX**

Female Spayed

**AGE**

11 years

**WEIGHT**

49lbs

**INTERPRETED BY**

Maggie Machen  
 Lamy, DVM  
 DACVIM (Cardiology)

**IMAGING PERFORMED BY**

Pamela Harrigan,  
 RDCS

**HOSPITAL NAME**

VCA Palmer

**REFERRING VET**

Dr. Boudreau

**INVOICE**

29111

**DATE**

2/20/23

VPCs are a very non-specific finding. They can be primary in origin (arrhythmic disease; a rule out diagnosis), develop secondary to significant cardiac disease (not present in this study), or be extra-cardiac in origin, i.e., due to pain, stress, inflammation, cancer, GI disease, DIC/sepsis, etc. In this senior boxer without structural cardiac disease, primary ARVC is certainly a possibility, That being said, consider ruling out all differentials as well given that the typical age of onset is 5-9 years old. The abdominal ultrasound, full lab work, etc. is recommended. Unfortunately, there is always an elevated risk for collapse and sudden death in any arrhythmic patient, and even on medications this risk unfortunately still persists.

In addressing arrhythmias in dogs, we must not only consider why they are happening as above, but also whether or not treatment is warranted. Given low markers of malignancy, consider application of a holter monitor prior to determining If therapy is warranted. In an asymptomatic dog however, suspicion is low. A holter will tell us the frequency and complexity of the rhythm over 24 hours of normal activity. An alternative approach would be to simply monitor at home for symptoms and utilize a holter monitor should the patient begin to experience clinical signs such as lethargy or collapse, which is also reasonable. Discussion with the owner is advised.

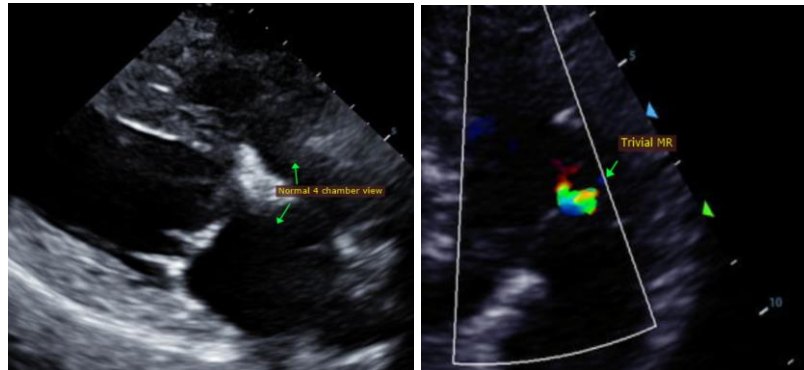
**RECOMMENDATIONS**

- No cardiac medications are clearly indicated at this time.
- Consider holter monitor as discussed.
- Consider full systemic evaluation.
- Fish oil supplementation is recommended for dogs with arrhythmias (1000-2000mg of omega 3 and 6 once to twice daily).
- If further evaluation is not performed, anesthetic risk is considered moderately elevated. Avoid ketamine, telazol, Dexdomitor (or other alpha-2 agonists) and acepromazine. Recommend having lidocaine CRI available for use in the event of worsening ventricular arrhythmias under anesthesia (CRI 50–75mcg/kg/min).
- Monitor at home for collapse, exercise intolerance, and/or lethargy.

**PLAN**

- If a holter monitor is elected, this will dictate whether additional therapy is needed and follow up protocol. If a holter is declined, recommend recheck ECG in 4-6 months.

**IMAGES**





**PATIENT**

Carter Lincoln

**SPECIES**

Canine

**BREED**

Boxer

**SEX**

Female Spayed

**AGE**

11 years

**WEIGHT**

49lbs

**INTERPRETED BY**

Maggie Machen  
Lamy, DVM  
DACVIM (Cardiology)

**IMAGING  
PERFORMED BY**

Pamela Harrigan,  
RDCS

**HOSPITAL NAME**

VCA Palmer

**REFERRING VET**

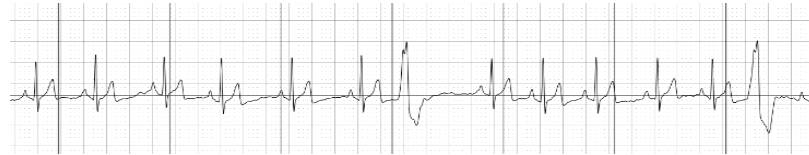
Dr. Boudreau

**INVOICE**

29111

**DATE**

2/20/23



The information and recommendations provided are based on the images presented by the referring veterinarian. No evaluation can be communicated regarding pathology that was not visible in the image/video clips provided.

Thank you for this referral. This report was generated using transcription software, and minor dictation errors may be present. If the clinical or image interpretation does not parallel your findings or if I can be of any further assistance, please contact me.

**Maggie Machen Lamy, DVM**  
Diplomate of the American College of Veterinary Internal Medicine (Cardiology)  
info@sonopath.com

**Echocardiogram performed by:** Pamela Harrigan, RDCS  
Pet Animal Ultrasound Service ([4paus.com](http://4paus.com))